

## Effect of n-Hexane extract of *Nigella sativa* on gentamicin-induced nephrotoxicity in rats

Nasim A. Begum, Zesmin F. Dewan, Nilufar Nahar,<sup>1</sup> and MI Rouf Mamun<sup>1</sup>

Department of Pharmacology, Bangabandhu Sheikh Mujib Medical University, Shahbag, Dhaka 1000, Bangladesh;

<sup>1</sup>Department of Chemistry, University of Dhaka, Dhaka 1000, Bangladesh

[Received 9 January 2006; Revised form received 1 February 2006]

### Abstract

The present study investigated whether the administration of the n-hexane extract of the *Nigella sativa* Linn. (kalajira) ameliorates gentamicin-induced nephrotoxicity in rats. Gentamicin (100 mg/kg/day for 7 days) was administered and nephrotoxicity was evaluated biochemically (significantly decreased reduced glutathione in renal cortex and significantly increased serum creatinine and serum urea) and histologically (moderate degree of proximal tubular damage). The n-hexane extract of *N. sativa* (5 ml/kg/day) was administered as pre-, post- and concomitant treatment for 7 days in the nephrotoxic rats. Statistically significant amelioration in all the biochemical parameters supported by significantly improved renal cortical histology was observed in the n-hexane extract of *N. sativa* treated nephrotoxic rats, which was more evident in the post-treatment group than the pre-treatment and the concomitantly-treated group. It is suggested that some ingredients contained in the n-hexane extract of *N. sativa* effected in ameliorating the signs of nephrotoxicity and that the specific active principle of the n-hexane extract of *N. sativa* responsible for this amelioration if obtained, would be more useful.

**Key words:** gentamicin, nephrotoxicity, n-hexane extract, *Nigella sativa*

### Introduction

Gentamicin is an important aminoglycoside antibiotic commonly used in treating life-threatening gram-negative infections (Ali, 1995). However its usefulness is limited by signs of nephrotoxicity, which may occur in 13-30% of treated patients (Mathew, 1992). Lipid peroxidation may occur in the course of gentamicin administration (Ramsamy et al., 1985), giving rise to free radicals (Yang et al., 1995), which are highly toxic to tissue (Feldman et al., 1982). Oxidation and necrosis by apoptosis may occur.

Antioxidants have been shown to ameliorate signs of gentamicin-induced nephrotoxicity (Ali and

Mousa, 2001). A recent study suggested that *N. sativa* oil (Ali, 2004) given prophylactically was able to alleviate gentamicin nephrotoxicity in rats. *N. sativa* (kalajira) occupies a unique position among the herbal products of Southeast Asia as a natural remedy for a number of illnesses. Its antibacterial, hypolipidaemic, antidiabetic and anti-hypertensive properties have been reported (Ara, 1999; Saha, 2004; Uddin, 2002; Rashid et al., 1987). The seeds or compounds isolated have been found to be useful in a number of models of nephrotoxicity. The phytochemical, pharmacological and toxicological properties of *N. sativa* have recently been reviewed (Ali and Blunden, 2003). Attempts were made to obtain agents that can ameliorate or potentiate the nephrotoxicity of gentamicin (Ali, 2003; Mingeot-Leclercq and Tulkens, 1999). Among these agents, extract of

for correspondence: Nasim A. Begum, Department of Pharmacology, Bangabandhu Sheikh Mujib Medical University, Shahbag, Dhaka 1000, Bangladesh;  
Phone: 8802-8013804; e-mail: drnasima@gmail.com

medicinal plants like garlic (Pedraza-Chaverri et al., 2000), and *N. sativa* oil (Ali, 2004) have been reported to possess properties to ameliorate gentamicin-induced nephrotoxicity. One common feature of the herbal agents is that they all have antioxidant properties (Prasad et al., 1996; Burits and Bucar, 2000). A potential therapeutic approach to ameliorate gentamicin-induced renal damage would have very important clinical consequence (Mengeot-Leclercq and Tulkens, 1999).

In the present work, we have attempted to test and compare the possible pre-, post- and concomitant action of n-hexane extract of *N. sativa* on gentamicin-induced nephrotoxicity in rats.

## Materials and methods

**Chemicals and reagents:** Gentamicin (80 mg/ml) was obtained from the Essential Drug Company Ltd. (Bangladesh). *N. sativa* was purchased from the local market. Chemicals and reagents of estimation of serum creatinine and serum urea were obtained from Human GmbH (Germany). Reduced glutathione was purchased from Loba Cheme (India). 5,5-dithiobis-2-nitrobenzoic acid (DTNB) was from Sigma Chemicals (USA).

**n-hexane extract of *N. sativa*:** The seeds of *N. sativa* (800 g) were soaked in 3 liters of n-hexane for 48-72 hr. They were filtered and the filtrate was concentrated in a rotary evaporator. The concentrate was freeze-dried, and a concentrated dark brown oily n-hexane extract of *N. sativa* was obtained.

**Animals:** Adult male rats aged between 8-12 weeks, weighing 200-230 g were obtained from the animal house of Bangabandhu Sheikh Mujib Medical University. Normal rat-feed, water *ad libitum* was provided under 12-hour light and 12-hour dark schedule at room temperature (24-28°C). Rats were divided into 12 groups, 6 rats in each control group and 10 rats in each experimental group.

**Experimental design:** Rats were treated with distilled water (2.5 ml/kg/day orally), gentamicin (100 mg/kg/day by subcutaneous injection),

soybean oil (5 ml/kg/day orally) or extract of *N. sativa* (5 ml/kg/ day orally) for 7 days followed by none or above concentration of distilled water, gentamicin, soybean oil or extract of *N. sativa* for another 7 days. Rats were sacrificed on either day 8<sup>th</sup> or 15<sup>th</sup>. 2 ml of blood was collected in clean test tubes and centrifuged (4000 x g for 5 min). The serum obtained was stored at 0-4°C for estimation of creatinine and urea concentrations. The kidneys were excised, blotted on a filter paper and weighed in pairs. The cortex was dissected out and a portion was placed in formalin for subsequent histological processing. Another portion of the renal cortex was processed for biochemical estimation of reduced glutathion (GSH) concentration.

**Biochemical measurements:** GSH concentration was measured in homogenates of the renal cortex spectrophotometrically (Sedlak and Lindsay, 1968). Serum creatinine concentration was measured by Jaffè reaction (Spencer, 1986). Serum urea concentration was measured by enzymatic colorimetric method (Fawcett and Scott, 1960).

**Histological procedure:** Small portion of cortex of the representative kidneys were fixed in 10% formalin, dehydrate in graded alcohol and embedded in paraffin wax, sectioned at 5 µm thickness and stained with Hematoxylin and Eosin (H&E) for light microscopic examination. Renal proximal tubular damage was assessed on the basis of arbitrary score (Teixeira et al., 1982) as follows: 0 for no cell necrosis; 1 for mild, usually single cell necrosis in sparse tubules; 2 for moderate, sparse tubules showing more than one cell involvement; 3 for marked, tubules in almost every power field exhibiting total necrosis; and 4 for massive, total necrosis.

**Protein analysis:** Protein content was determined by Biuret method (Weichselbaum et al., 1946)

**Statistical analysis:** The results obtained from the experiments are represented as mean ± SEM of the number of samples. Data were analyzed by Student's unpaired 't' test, and significant difference between means ± SEM of the different groups were estimated using one-way analysis of

variance (ANOVA) followed by Student's unpaired 't' test.

## Results

The groups of rats injected subcutaneously with gentamicin for 7 days, sacrificed on day 8 and 15 had serum creatinine and serum urea concentrations significantly ( $P < 0.001$ ) increased while the renal cortical reduced glutathione concentrations of these groups of rats were significantly reduced ( $P < 0.001$ ) compared to those in the control rats. This would suggest that these rats were made model for nephrotoxicity (Table I). This assumption was supported by histological observation of the H&E stained transverse sections through the renal cortex, which suggested massive damage to the proximal tubules (score 3) of these groups of rats (Fig. 1b). The transverse sections through the renal cortex of the vehicle control groups of rats showed almost identical architecture with no damage to proximal tubules (Fig. 1a). The n-hexane extract of *N. sativa* treated rats differed from the vehicle control rats by an elevated

( $P < 0.001$ ) concentration of renal cortical reduced glutathione, while the other biochemical parameters were identical (no statistical difference could be obtained) almost to those of the control rats, and the histology did not differ from those of the control groups of rats. Treatment of nephrotoxic rats with the n-hexane extract of *N. sativa* as pre-, post- and concomitantly mitigated the increases in serum creatinine and urea, and the decreases in reduced glutathione (GSH) while compared to those of the gentamicin-treated group sacrificed on day 15 (Table I). But none of the parameters in any of the groups were identical or closer to those of the control groups (Table I). However, the post-treatment group (gentamicin followed by n-hexane extract of *N. sativa*) demonstrated significant reduction in serum creatinine and serum urea concentrations ( $P < 0.001$ ) and also a significant elevation ( $P < 0.001$ ) of renal cortical glutathione concentrations compared to those observed in the pre treatment group (n-hexane extract of *N. sativa* followed by gentamicin) and the concomitantly treated (gentamicin

**Table I:** Effects of gentamicin and n-hexane extract (*N. sativa*) on biochemical parameters and histology

Duration of treatment			n	Cortical GSH (mg/g protein)	Serum creatinine (mg/dl)	Histological score	P value, Group vs Group
Sacrificed on day 8							
Group	First week	Second week					
1	Distilled water	-	6	2.21 ± 0.01	0.39 ± 0.01	0	
2	Gentamicin	-	10	1.01 ± 0.01	3.09 ± 0.11	3	<0.001, 1 vs 2
3	Soybean oil	-	6	2.20 ± 0.02	0.39 ± 0.01	0	
4	Extract of <i>N. sativa</i>	-	10	5.71 ± 0.01	0.38 ± 0.01	0	<0.001, 3 vs 4
Sacrificed on day 15							
Group	First week	Second week					
5	Distilled water	None	6	2.21 ± 0.01	0.39 ± 0.01	0	
6	Gentamicin	None	10	1.09 ± 0.03	2.90 ± 0.05	3	<0.001, 5 vs 6 >0.05, 2 vs 6
7	Soybean oil	Distilled water	6	2.21 ± 0.01	0.39 ± 0.01	0	
8	Extract of <i>N. sativa</i>	Gentamicin	10	1.68 ± 0.02	0.75 ± 0.02	2	<0.001, 6 vs 8; 7 vs 8
9	Distilled water	Soybean oil	6	2.20 ± 0.02	0.39 ± 0.01	0	
10	Gentamicin	Extract of <i>N. sativa</i>	10	2.01 ± 0.02	0.57 ± 0.02	0	<0.001, 6 vs 10; 8 vs 10; 9 vs 10
11	Distilled water and soybean oil	None	6	2.21 ± 0.01	0.39 ± 0.01	0	
12	Gentamicin and extract of <i>N. sativa</i>	None	10	1.75 ± 0.02	0.68 ± 0.02	2	<0.001, 6 vs 12; 10 vs 12; 11 vs 12; <0.05, 8 vs 12

Dosage: distilled water (2.5 ml/kg/day orally); gentamicin (100 mg/kg/day by subcutaneous injection); soybean oil (5 ml/kg/day orally); n-hexane extract of *N. sativa* (5 ml/kg/day orally); Values are means ± SEM;

and n-hexane extract of *N. sativa* concomitantly treated). Histological picture obtained in the post

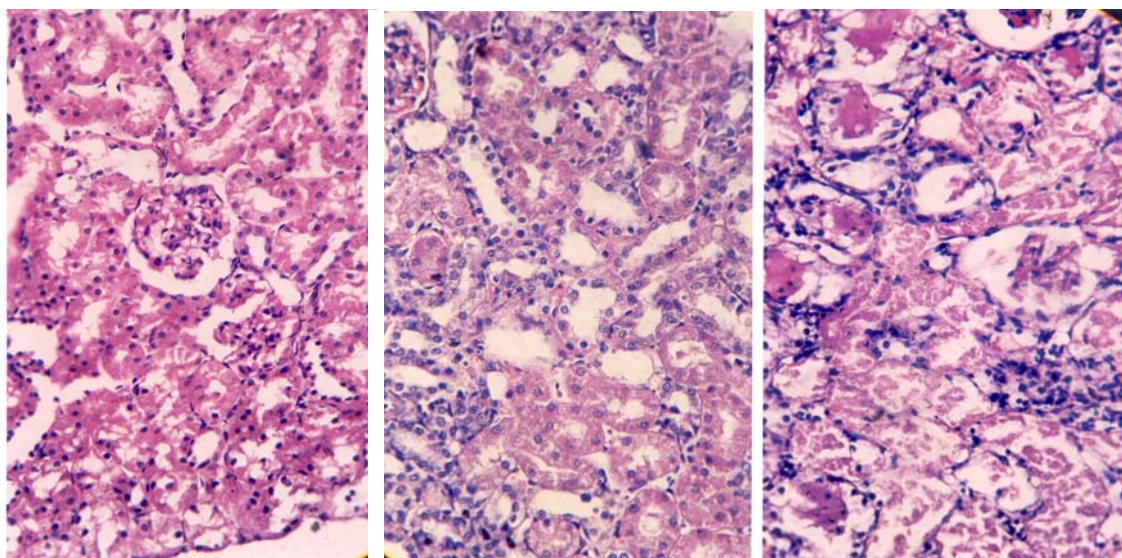
treatment was also apparently improved (score 1). However, the histological score obtained in both

the pre treatment and concomitantly treated group were score 2. The post-treatment, therefore, remained as the most alleviated treatment group from toxic damage of gentamicin (Fig. 1c).

## Discussion

In the present study, nephrotoxicity induced by gentamicin was evidenced by depletion of renal cortical GSH and increases in serum creatinine and serum urea concentrations. This was supported by proximal tubular histology suggestive of gross tubular damage. These observations were similar to those of Ali (2004) who reported similar biochemical and histological changes suggestive of nephrotoxicity. The n-hexane extract of *N. sativa* possess strong antioxidant properties (Badary et al., 2000; Burtis and Bucar, 2000) that is why they were used in the present study to expect that the action of the toxic free radicals (Feldman et al., 1982) in the course of gentamicin

administration, causing oxidative damage to the renal cortex would be antagonized. Reports about similar ameliorating action of antioxidants upon gentamicin nephrotoxicity is available (Ali and Mousa, 2001; Naidu et al., 2000; Ali, 2004). We have used three treatment groups to ameliorate gentamicin nephrotoxicity e.g., the n-hexane extract of *N. sativa* followed by gentamicin (pre-treatment), gentamicin followed by n-hexane extract of *N. sativa* (post treatment) and lastly, concomitant administration of gentamicin and the n-hexane extract of *N. sativa* (concomitant treatment). The results of biochemical and histological observations indicate that the groups of rat which received gentamicin followed by n-hexane extract of *N. sativa* better overcome the toxic actions when compared to the other two groups. Gentamicin treatment in rats gives rise to free radicals (Walker and Shah, 1988; Yang et al., 1995) that induces oxidative damage at the cellular level of the renal cortex (Feldman et al.,



**Figure 1:** Representative photograph of sections of renal cortex under light-microscope of rats treated with either distilled water (a), gentamicin (100 mg/kg/day for 7 days (b) and gentamicin plus extract of *N. sativa* (5 ml/kg/day for next 7 days)(c). H&E 400 x

1982). Agents with antioxidant action could antagonize the depletion of the reduced glutathione (Sandhya and Varalakshmi, 1997; Pedraza-Chaverri et al., 2000; Ali, 2004). Probably the antioxidant action of the n-hexane extract of *N. sativa* prevents the oxidation of renal tissue. The cellular GSH content was therefore not depleted.

In conclusion the present study suggests that the n-hexane extract of *N. sativa* was able to produce considerable alleviation from the nephrotoxic action of gentamicin in the adult male rats. The antioxidant action perhaps better exerted in presence of oxidative damage and prior supply of antioxidant may not protect the tissue to the expected degree in absence of free radicals. The

mechanism of alleviation and the specific dose and ingredients of the n-hexane extract of *N. sativa* for complete nephroprotection remains to be identified.

## References

- Ali BH. Gentamicin nephrotoxicity in humans and animals: Some recent research. *Gen Pharmacol.* 1995; 26: 1477-87.
- Ali BH. Agents ameliorating or augments the nephrotoxicity of gentamicin: Some recent research. *Food Chem Toxicol.* 2003; 41: 1434-39.
- Ali BH. The effect of *Nigella sativa* oil on gentamicin nephrotoxicity in rats. *Am J Chin Med.* 2004; 32: 49-55
- Ali BH, Blunden G. Pharmacological and toxicological properties of *Nigella sativa*. *Phytother Res.* 2003; 17: 299-305.
- Ali BH, Mousa HM. Effect of dimethyl sulfoxide on gentamicin-induced nephrotoxicity in rats. *Human Exp Toxicol.* 2001; 20:199-203.
- Ara N. Antimicrobial activity of the volatile oil of *Nigella sativa* Linn. Seeds. MPhil thesis. Bangabandhu Sheikh Mujib Medical University, Dhaka. 1999.
- Badary OA, Abdel-Naim AB, Abdel-Wahab MH, Hamada FMA. The influence of thymoquinone on doxorubicin-induced hyperlipidemic nephropathy in rats. *Toxicology* 2000; 143: 219-26.
- Burits M, Bucar F. Antioxidant activity of *Nigella sativa* essential oil. *Phytother Res.* 2000; 14: 323-08.
- Fawcett JK, Scott JE. A rapid and precise method for the determination of urea. *J Clin Path.* 1960; 13:156.
- Feldman S, Wang M, Kaloyanides GJ. Aminoglycosides induce a phospholipidosis in the renal cortex of the rat: An early manifestation of nephrotoxicity. *J Pharmacol Exp Therp.* 1982; 220: 514-20.
- Mathew TH. Drug-induced renal disease. *Med J Aust.* 1992; 156: 724-28.
- Mingeot-Leclercq M, Tulkens PM. Aminoglycosides: nephrotoxicities. *Antimicrobial Agents Chemother.* 1999; 43: 1003-12.
- Naidu MU, Shifow AA, Kumar KV, Ratnaker KS. Ginkgobiloba extract ameliorates gentamicin-induced nephrotoxicity in rats. *Phytomedicine* 2000; 7: 191-97.
- Pedraza-Chaverri J, Maldonado PD, Medina-Champos N, Olivares-Corichi IM, Granados-Silvestre ML, Hernandez-Pando R, *et al.* Garlic ameliorates gentamicin nephrotoxicity: relation to antioxidant enzymes. *Free Rad Biol Med.* 2000; 29: 602-11.
- Prasad K, Laxdal VA, Yu M, Raney BL. Evaluation of hydroxyl radical-scavenging property of garlic. *Mol Cell Biochem.* 1996; 154: 55-63.
- Ramsammy L, Ling KY, Josepovitz C, Levine R, Kaloyanides GJ. Effect of gentamicin on lipid peroxidation in rat renal cortex. *Biochem Pharmacol.* 1985; 34: 3895-900.
- Rashid MA, Rahman S, Chowdhury SAR, Ahmed M, Chowdhury AKA. Primary screening of some herbal products of Bangladesh for antihypertensive activity. *Bangladesh J Neuro.* 1987; 3: 56-58.
- Saha RR, Dewan ZF, Uddin N. Effect of *Nigella sativa* Linn (kalajira) on serum lipid profile of hyperlipidemic rats. *Bangladesh J Physiol Pharmacol.* 2004; 20: 36-38.
- Sandhya P, Varalakshmi P. Effect of lipoic acid administration on gentamicin-induced lipid peroxidation in rats. *J Appl Toxicol.* 1997; 17: 405-08.
- Sedlak J, Lindsay RH. Estimation of total, protein-bound and non-protein sulfhydryl groups in tissue with Elman's reagent. *Anal Biochem.* 1968; 25: 192-205.
- Spencer K. Analytical reviews in clinical biochemistry: the estimation of creatinine. *Ann Clin Biochem.* 1986; 23:1-25.
- Teixeira RB, Kelley J, Alpert H, Pardo V, Vaamonde CA. Complete protection from gentamicin-induced acute renal failure in diabetes mellitus rats. *Kidney Int.* 1982; 21: 600-12.
- Uddin N, Dewan ZF, Zaman M, Saha RR, Sultana M. Effects of *Nigella sativa* Linn. (kalajira) on serum glucose concentration in streptozotocin-induced diabetic rats. *Bangladesh J Physiol Pharmacol.* 2002; 18: 6-9.
- Walker PD, Shah SV. Evidence suggesting a role of hydroxyl radical in gentamicin-induced acute renal failure in rats. *J Clin Invest.* 1988; 81:334-41.
- Weichselbaum TE. Estimation of serum total protein by Biuret method. *Am J Clin Path.* 1946; 16: 40-48.
- Yang C, Du X, Han Y. Renal cortical mitochondria are the source of oxygen free radicals enhanced by gentamicin. *Renal Fail.* 1995; 17: 21-26.