

## Pre-treatment by *n*-hexane extract of *Phyllanthus niruri* can alleviate paracetamol-induced damage of the rat liver

<sup>1</sup>Md. Jalaluddin Iqbal, <sup>1</sup>Fauzia Z. Dewan, <sup>1</sup>S.A.R. Chowdhury, <sup>2</sup>M.I.R. Mamun,  
<sup>2</sup>M. Moshuazzaman and <sup>3</sup>Monowara Begum

<sup>1</sup>Department of Pharmacology, Bangabandhu Sheikh Mujib Medical University, Shahbag, Dhaka;

<sup>2</sup>Department of Chemistry, University of Dhaka, Dhaka;

<sup>3</sup>Essential Oil Section, Bangladesh Council of Scientific and Industrial Research, Dhaka, Bangladesh.

[Received 12 April 2007]

### Abstract

The present study aimed to obtain and evaluate remedy against viral hepatitis with *Phyllanthus niruri* (Bhui amla). Viral infection and toxic doses of paracetamol produce similar pattern of hepatotoxicity. Hepatotoxicity was induced by administering paracetamol (750 mg/kg body weight, single dose intraperitoneal) into one group (group P) of rats. Propylene glycol (vehicle) was administered (2 ml) into another group (group V) of rats. 4 groups of *P. niruri* extract-pretreated (200 mg/kg body weight/day for 7 days) rats were administered the same single dose of paracetamol on the 7th day. Extract of *P. niruri* were obtained through ethanol (E), hexane (H), dichloromethane (D) and butane (B). Rat groups were V, P, E + P, H + P, D + P and B + P. Each group consisted of 6 rats and were sacrificed on the 9th day. Parameters for evaluation were biochemical (serum ALT, serum AST, serum ALP, serum bilirubin), hepatic reduced glutathione concentrations and hepatic histology. Propylene glycol (group V) appeared non-toxic to the liver while significant degrees of centrilobular hepatotoxicity was observed in group P paracetamol-treated rats. The E + P group suggested significant improvements in the serum parameters but these parameters appeared better alleviated in the H + P group. Hepatic reduced glutathione concentrations were replenished to the control level in both E + P and H + P groups. Hepatic histology supported biochemical and other observations in the P, E + P and H + P groups. Lesser degrees of alleviations were observed in the D + P and B + P groups. However, the hexane extract-pretreated group (H + P) appeared to provide the most significant hepatoprotection against paracetamol induced hepatotoxicity in the rat. Titration of the dose following isolation of the active ingredient might offer complete alleviation.

**Kew words:** butanol, dichloromethane, ethanol, extract, hexane, paracetamol, *Phyllanthus niruri*, rat

### Introduction

*Phyllanthus niruri* (Bhui amla) is a well-known herb of Bangladesh and the sub-continent. It is an indigenous medicinal plant, the medicinal potentials of which was well known to the rural people and has been utilized by local medical practitioners in the treatment of different human ailments including liver diseases, diabetes mellitus, gonorrhoea etc (Kirtikar and Basu, 1984; Dastar, 1988). A report by Saha (1998) has stated that the ethanol extract of *P. niruri* can produce

alleviations of paracetamol-induced hepatotoxicity in the rat.

The efficacy of the aqueous extract of *P. niruri* to inhibit the development of endogenous DNA polymerase of hepatitis B virus bind to the surface antigen of hepatitis B virus (in vitro) has been reported (Venkateshwaran et al., 1987), and was perhaps the mechanism of alleviation of the virus-induced damages.

These reports appeared encouraging to the present researches. The incidence of viral hepatitis is being increased now-a-days in South Asia region including Bangladesh. The presently

for correspondence: Md. Jalaluddin Iqbal, Department of Pharmacology, Sir Salimullah Medical College, Mitford, Dhaka, Bangladesh.

available treatment offered to the patients of viral hepatitis does not always bring successful results besides being costly. Attempts are on-going to obtain better treatment modalities for viral hepatitis. The hepatotoxicity induced by paracetamol appears identical to that produced by viral infections (Maddrey and Boitnott, 1977, cited by Islam, 1999). It was assumed that if *P. niruri* could alleviate paracetamol-induced hepatotoxicity, it could alleviate viral hepatitis. If curative potentials of *P. niruri* against viral hepatitis could be established (because herbal products are of lesser adverse effects), that might be of great help to mankind. The report by Saha (1998) has stated about hepatoprotective potentials in the ethanol extract of *P. niruri*. The present study aimed to obtain and evaluate hepatoprotective potentials in 4 extracts of *P. niruri* (e.g., ethanol, hexane, dichloromethane

and butane) on a pretreatment basis. Paracetamol was chosen to induce hepatotoxicity in the rat model.

## Materials and Methods

Thirty six adult Long Evans rats were taken from the animal house of BCSIR, Dhaka. They were divided into 6 groups each group containing of 6 rats. The rats were housed in metallic cages as 3 rats per cage under 12 hours light and 12 hour dark schedule in well ventilated room. Rat chow and water *ad libitum* were provided. The schedule of administration of vehicle (V), paracetamol (P), ethanol extract (E), Hexane extract (H), dichloromethane extract (D) and butane extract (B) of *P. niruri* are presented in Table I.

**Table I:** Schedule of vehicle, paracetamol and *Phyllanthus niruri* extracts administration on a pre-treatment basis

Groups	n	Drug/vehicle/extract (single/combination)	Dose	Duration (day)	Sacrifice (day)
V	6	Propylene glycol	2 ml/rat	1st	3rd
P	6	Paracetamol	750 mg/kg	7th	9th
E + P	6	Ethanol extract of <i>P. niruri</i> plus Paracetamol	200 mg/kg 750 mg/kg	1-7 7th	9th
H + P	6	Hexane extract of <i>P. niruri</i> plus Paracetamol	200 mg/kg 750 mg/kg	1-7 7th	9th
D + P	6	Dichloromethane extract of <i>P. niruri</i> plus Paracetamol	200 mg/kg 750 mg/kg	1-7 7th	9th
B + P	6	Butane extract of <i>P. niruri</i> plus Paracetamol	200 mg/kg 750 mg/kg	1-7 7th	9th

The vehicle treated group received a single dose of vehicle for paracetamol (propylene glycol), at a dose of 2 ml each rat orally by means of stomach tube on day 1.

The paracetamol treated group received a single dose of paracetamol (750 mg/kg body weight) in propylene glycol by intraperitoneal injection on the 7th day only.

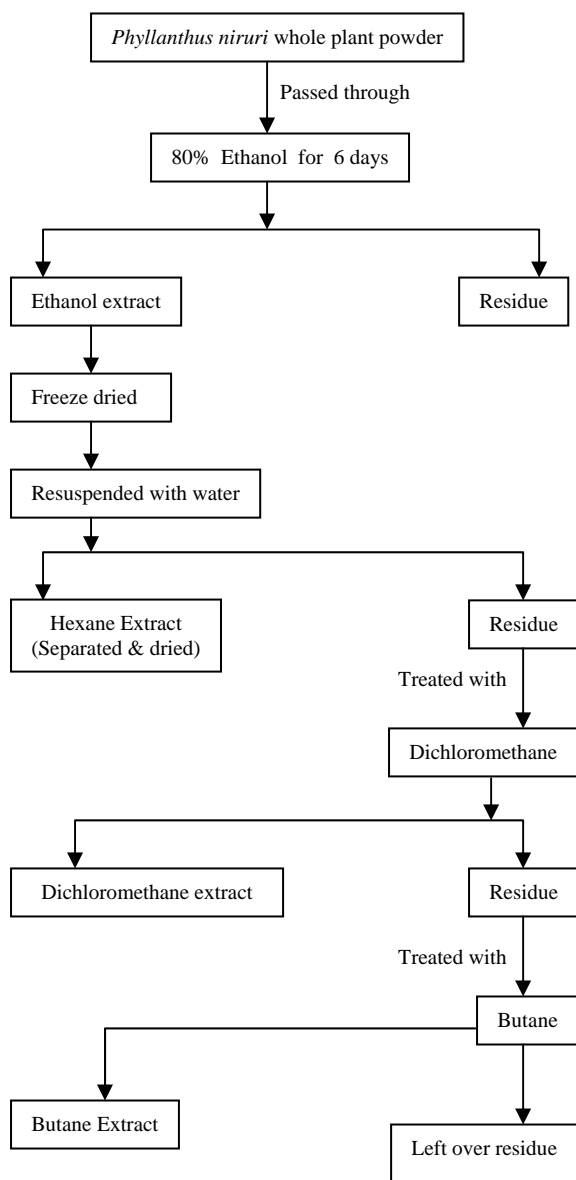
The extracts of *P. niruri* were administered into each rat intraperitoneally at a dose of 200 mg/kg body weight/day from day 1-7 (pre-treatment).

Drug/chemicals/extracts were administered in the morning as has been described by Futter et al., (2001) following overnight starvation for 16

hours (Walker, 1974). All rats were sacrificed on the 9th day.

*Extraction of P. niruri:* Root free whole plants were cleaned and dried in air oven at 40°C, then crushed into powder by a cyclotec grinding machine and kept in stoppered container. Suspension of the 4 extracts were made in propylene glycol and administered orally at a dose of 200 mg/kg body weight/day (Saha, 1998) for 7 consecutive days.

*Sacrifice of the rats:* Rats were sacrificed on the 9th day under ether anesthesia. Blood was collected from the carotid artery, centrifuged at 4,000 rpm. Serum was preserved at 0°C in small



**Figure 1:** Scheme for obtaining the 4 extracts of *Phyllanthus niruri*

ependorf tubes until biochemical estimations were carried out. Parameters studied were serum alanine transferase (ALT), serum aspartate (AST), serum alkaline phosphatase, serum bilirubin, hepatic reduced glutathione (GSH) concentrations and architectural changes of the hepatic structure and its alleviation.

**Procedure for hepatic GSH estimation and histology:** The liver was taken out by giving a median incision in the abdomen of the rat. Each liver was weighed out and then placed upon ice. For histology, a portion of each liver was preserved in formalin. The rest of each liver was kept at  $-20^{\circ}\text{C}$  until homogenized. The portion of liver that was kept in formalin was fixed in wax, blocks were made and transverse section was cut at  $5\mu\text{m}$  thickness by microtome. The sections were dried and later stained by hematoxylin and eosin (H & E). The stained sections were examined under Olympus microscope. Grades were attributed to mark the degree of hepatocyte and centrilobular necrosis.

## Results

The mean  $\pm$  S.E concentrations of serum ALT in vehicle treated rats (group V) were  $27.27 \pm 3.58$  U/ml. In group P, this was  $78.03 \pm 5.60$  U/ml (Table II). The serum alkaline phosphatase concentrations in the E + P, H + P, D + P and B + P groups were  $26.20 \pm 2.07$ ,  $20.53 \pm 2.73$ ,  $53.23 \pm 8.19$  and  $62.20 \pm 6.46$  U/ml respectively.

**Table II:** Effect of pretreatment of the extracts of *Phyllanthus niruri* on liver function test and reduced glutathione concentrations in liver in paracetamol treated rats

Parameters	Vehicle	Paracetamol	Ethanol extract+ Paracetamol	Hexane extract + Paracetamol	Dichloromethane extract + Paracetamol	Butanol extract + Paracetamol
ALT (U/l)	$27.27 \pm 3.58$	$75.08 \pm 3.40$	$26.20 \pm 2.07$	$20.53 \pm 2.73$	$53.23 \pm 8.19$	$62.20 \pm 6.46$
AST (U/l)	$37.87 \pm 4.69$	$127.83 \pm 6.21$	$49.67 \pm 4.50$	$29.85 \pm 4.45$	$48.50 \pm 6.21$	$98.40 \pm 6.06$
Alkaline phosphatase (U/l)	$91.77 \pm 5.02$	$159.42 \pm 11.14$	$95.33 \pm 9.54$	$134.43 \pm 24.41$	$109.07 \pm 8.46$	$102.03 \pm 11.03$
Serum bilirubin (mg/dl)	$0.37 \pm 0.06$	$0.46 \pm 0.07$	$0.38 \pm 0.03$	$0.26 \pm 0.03$	$0.41 \pm 0.06$	$0.49 \pm 0.08$
GSH ( $\mu$ mole/gm)	$10.44 \pm 0.36$	$6.35 \pm 0.28$	$10.88 \pm 0.51$	$10.35 \pm 0.54$	$8.53 \pm 0.05$	$7.13 \pm 0.32$

Data are expressed as mean  $\pm$  SE. In each group n = 6.

The concentrations of serum AST in the V group were  $37.87 \pm 4.69$  U/ml, which was  $127.83 \pm 6.21$  in the P group,  $49.67 \pm 4.50$  U/ml in the E + P group,  $29.85 \pm 4.45$  U/ml in the H + P group,  $48.50 \pm 6.21$  in the D + P group and  $98.40 \pm 6.06$  U/ml in the B + P group. The serum alkaline phosphatase (mean  $\pm$  SE) in the V group was  $91.77 \pm 5.02$  U/ml, which was  $159.42 \pm 11.14$  U/ml. In the 4 extract groups the serum ALP concentrations were  $95.33 \pm 9.54$  u/l,  $134.43 \pm 24.41$  u/L,  $109.07 \pm 8.46$  u/l and  $102.03 \pm 11.03$  u/L in E + P, H + P, D + P and B + P groups respectively.

The serum bilirubin concentrations in the V group were  $0.37 \pm 0.06$  mg/dl, demonstrating a significant ( $P < 0.05$ ) increase in the P group ( $0.46 \pm 0.07$  mg/dl). Pre-treatment with the 4 extracts had produced the estimations e.g.  $0.38 \pm 0.03$  mg/dl (E + P group),  $0.26 \pm 0.03$  mg/dl (H + P group),  $0.41 \pm 0.06$  mg/dl (D + P group) and  $0.49 \pm 0.08$  mg/dl (B + P group).

The (mean  $\pm$  SE) concentrations of GSH in liver homogenates of the V group were  $10.44 \pm 0.36$   $\mu$ mol/gm, which were significantly ( $p < 0.001$ ) reduced in the P group ( $6.35 \pm 0.28$   $\mu$ mol/gm) (Table II). Pre-treatment with the 4 extracts had obtained the following estimations of reduces glutathione e.g.  $10.35 \pm 0.54$   $\mu$ mol/gm (H + P group),  $8.53 \pm 0.05$   $\mu$ mol/gm (D + P group) and  $7.13 \pm 0.03$   $\mu$ mol/gm (B + P group).

**Table III.** Grade of liver necrosis in rats after pre treatment with protective drug plus paracetamol

Group	No. of rats	Grade of necrosis				
		0	I	II	III	IV
V	6	6				
P	6			3	3	
P	6		1	2	3	
E + P	6	4	2			
H + P	6	4	2			
D + P	6	3	2			
B + P	6	1	3	2		

Hepatic necrosis measured in grades in the V group was '0' indicating no hepatocellular damage. In the P group, 3 rats (50%) demonstrated grade II and 3 rats (50%) had shown grade III necrosis (Table III). In the E + P,

H + P, D + P and B + P groups, grade '0' necrosis were observed in 4(64%), 4(64%), 3(50%) and 1(16.6%) rats respectively.

## Discussion

The present study attempted to evaluate the efficacy of the 4 extracts of *P. niruri* to alleviate paracetamol-induced hepatotoxicity in the rat model.

The biochemical measurements and the hepatic architectures of the V group appeared normal. However, all conventional indices of hepatic damage were significantly increased in group P, suggestive of hepatotoxicity. The reduced in liver homogenates of the P group, which also suggested that hepatic damage had occurred by paracetamol administration which hepatic section from the P group demonstrated irregularly arranged hepatocytes, necrotic tissue and debris. Congested sinusoids, kupffers cells and faint and irregular cellular outline could observe.

In the E+P group the mean concentrations of serum ALT, serum ALP, serum bilirubin and the reduced glutathione in liver homogenates did not differ from the V groups, although the serum AST remained high ( $P < 0.05$ ). Histology suggested 64% protection of the hepatic architecture, indicating significant alleviation. These findings correlate well with the findings from previous studies (Syamsuandeer et al., 1985, Venkateshwaran, 1987; Thyarayan, 1988; Mehrota, 1990; Wang, 1995; Saha, 1998 and Wang, 2000).

In the H+P group, the mean serum ALT, serum AST and serum bilirubin concentrations were at significantly ( $P < 0.001$ ) lower levels compared to those in group P. The value was closer to those in the control values (Group V) and the mean serum bilirubin concentrations remained at significantly lower levels than those in the V group. These observations suggest alleviation of hepatotoxicity and the assumption get support from reduced glutathione concentrations, the mean concentrations of which appeared almost at the same level to those of the V group. The improvement by the hexane extract pre-treatment was also evident in histology of the liver, although the serum alkaline phosphatase concentrations were not

remarkably improved ( $P < 0.05$ ) in the H + P group.

The D + P group had not demonstrated remarkable improvement in the biochemical parameters. Histological examination suggested that damage to the hepatic architecture persisted. The last group in the pre-treatment series i.e. the B+P group suggested even lesser improvement in both biochemical and histological examinations.

It appears from the available data and histology that the H + P group was better protected paracetamol toxicity, and the protection appeared better compound to those in the E + P group regarding serum AST and reduced glutathione concentrations in liver homogenous. Saha (1998) has reported protection by ethanol pretreatment. We offer hexane extrude of *P. niruri* as a better protectant compared to the ethanol extract. Perhaps the hepatoprotective ingredients including antioxidants vitamin A, vitamin C and glutathione replenishing agents e.g. cysteine and S + I groups (Ahmed et al., 1999) were better extracted during extraction with hexane. Mitchell et al. (1973) has reported the protective role of glutathione in rat (which was probably due to cysteine). Cysteine is one of the precursors of glutathione and replenishing cystenic stores can prevent hepatic damage.

Further study is necessary to isolate the specific ingredient(s) in the *n*-hexane extract of *P. niruri*.

## References

- Ahmed A, Pillai KK, Shibli J, Balani DK, Najmi AK, Marwah R, Hameed A. Evaluation of the hepatoprotective potential of jigrine pretreatment on thioacetamide induced liver damage in rats. *Indian J Pharmacol.* 1999; 31: 416-21.
- Black M. Acetaminophen hepatotoxicity. *Gastroenterology* 1980; 78: 382-92.
- Dastur JF. Medicinal plants of India and Pakistan. Bombay, Taraporevala Sons, 1988.
- Futter LE, al-Swayeh OA, Moore PK. A comparison of the effect of nitroparacetamol and paracetamol on liver injury. *Bri J Pharmacol.* 2001; 132: 10-12.
- Garg NK. Screening of natural product for hepatoprotective activity. Lucknow, Central Research Institute, 1995, pp 189-91.
- Hentze H, Gantner F, Kolb SA, Wendel A. Depletion of hepatic glutathione prevents death receptor-dependent apoptotic and necrotic liver injury in mice. *Am J Path.* 2000; 156: 2045-56.
- Islam MM. Effect of *Eclipta alba* and *Tinospora cordifolia*, Vitamin C and Vitamin E on paracetamol-induced hepatotoxicity in rat. MPhil thesis, BSMMU, 1999.
- Kirtikar KR, Basu BD. Indian medicinal plants. 2nd ed. International Book Distributors, Dehradun, 1984, pp 225-27.
- Maddrey WC, Boitnott JK. Progress in hepatology: drug-induced chronic liver disease. *Gastroenterology* 1977; 72: 1348-53.
- Mehrotra R. Rawat S, Kulshrestha DK, Patanaik GK, Dhawan BN; In vitro studies on the effect of certain natural products against hepatitis B virus. *Indian J Med Res.* 1990; 92: 133-38.
- Mitchell JR, Jollow DJ, Potter WZ, Davis DC, Gillette JR, Brodie BB. Acetaminophen-induced hepatic necrosis. I. Role of drug metabolism. *J Pharmacol Exp Ther.* 1973; 187: 185-94.
- Mitchell JR, Jollow DJ, Potter WZ, Gillette JR; Brodie BB. Acetaminophen-induced hepatic necrosis. II. Protective role of glutathione. *J Pharmacol Exp Ther.* 1973; 187: 211-17.
- Saha DR. Effects of *Phyllanthus niruri* on paracetamol-induced hepatotoxicity in rat. MPhil thesis, University of Dhaka, Dhaka, 1998.
- Souhami RL, Moxham J. Liver and biliary tract disease. Textbook of medicine, New York, Churchill Livingstone, 1990, 17: p 623.
- Syamasundar KV, Singh B, Thakur RS, Husain A, Kiso Y, Hikino H. Antihepatotoxic principles of *Phyllanthus niruri* herbs. *J Ethnopharmacol.* 1985; 14: 41-44.
- Thyagarajan SP, Thiruneelakantan K, Subramanian S, Sundaravelu T. In vitro inactivation of HBsAg by *Eclipta alba* Hassk and *Phyllanthus niruri* Linn. *Indian J Med Res.* 1982; 76 (Suppl): 124-30.
- Venkateswaran PS, Millman I, Blumberg BS. Effects of an extract of *Phyllanthus niruri* on hepatitis B and Woodchuck hepatitis viruses: In vitro and vivo studies. *Proc Natl Acad Sci USA.* 1987; 84: 274-78.
- Walker IS, Kelleher J, Dixon MF, Losowsky MS. Vitamin E protection of the liver from the paracetamol in the rats. *Clin Sci Mol Med.* 1974; 47: 449-59.
- Wang BE. Treatment of chronic liver diseases with traditional Chinese medicine. *J Gastroenterol Hepatol.* 2000; 15: 67-70.

Wang M, Cheng H, Li Y, Meng L, Zhao G, Mai K.  
Herbs of genus *Phyllanthus* in the treatment of  
chronic hepatitis B: Observations with three

preparations from different geographic sites. *J Lab  
Clin Med.* 1995; 126: 350-52.

---